



GERALD  
**SIMONDS**

[www.gerald-simonds.co.uk](http://www.gerald-simonds.co.uk)

**Independent clinical evaluation of Stimulite cushions  
conducted on behalf of Gerald Simonds Healthcare by  
Wounds Healing Centres UK Ltd. and Dr Steve Young.**

**April 2013**



# **Stimulite Cushions Clinical Trial Report**

## **Ultrasound Analysis**

### **Dr Steve Young**

Dr Young's experience into wound healing research extends back almost 30 years to 1983 when he joined the Tissue Repair Research Unit in the Department of Anatomy, Guy's Hospital Medical School, now part of King's College London (KCL), as the Deputy Head.

As well as carrying out research he was also an honorary senior lecturer in wound healing at the medical school. As part of the Tissue Repair Research Unit he was also responsible for supervising MSc and PhD students.

In 1995 Dr Young founded the Tissue Viability Unit at Guy's and was its Director until 2002. Since then he has worked as a biomedical consultant and is one of the inventors of a high-resolution diagnostic ultrasound scanner which is unique in that it acquire clinical information about the status of skin and wounds prior to it becoming clinically evident.

**26<sup>th</sup> April 2013**

## **Trial Design**

This pilot study was carried out by WHC in Eastbourne on patients with evidence of sacral pressure damage.

5 Patients were recruited for this trial

The trial design was as follows:

### **Visit 1**

- Patients identified and consented.
- Ultrasound scanning carried out on the damaged area of the sacrum to establish a baseline. Also, an area of normal skin adjacent to the damaged area was scanned to ascertain what the patient's uninjured skin looked like.

### **Visit 2**

- 14 days after the baseline visit the same areas were again scanned. From the information gained from this it was possible to establish if the area had improved, deteriorated or stagnated.

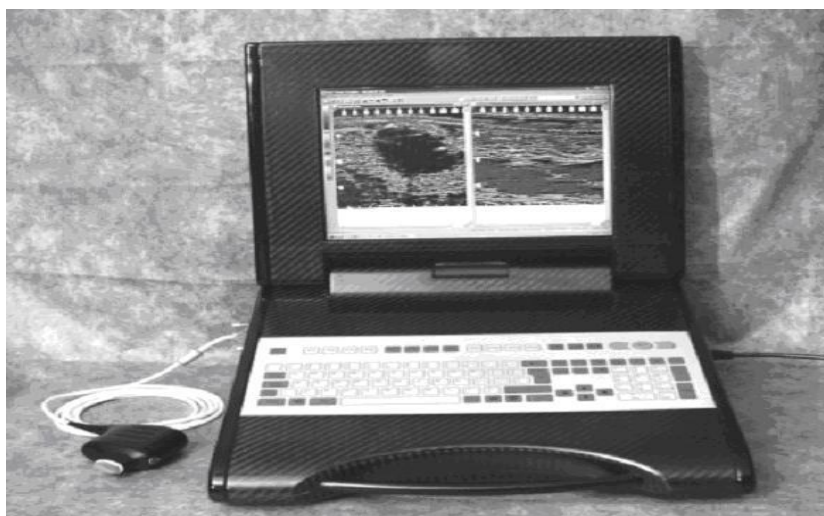## **Assessment:**

### ***Ultrasound Scanning:***

The benefit of including ultrasound as an assessment tool is that it provides quantitative information about what is happening beneath the skin surface which is not always clinically evident (1-6).

The scanner used in this project (figure 1) operated at a frequency of 20MHz (Episcan - Longport Inc.). This frequency gives an axial resolution of 65µm.

Figure 1. Ultrasound Scanner



The scanning procedure is non-invasive and the affected area was exposed and an aqueous gel applied to it and a scan then taken. Care was taken to carry out subsequent scans in the same area.

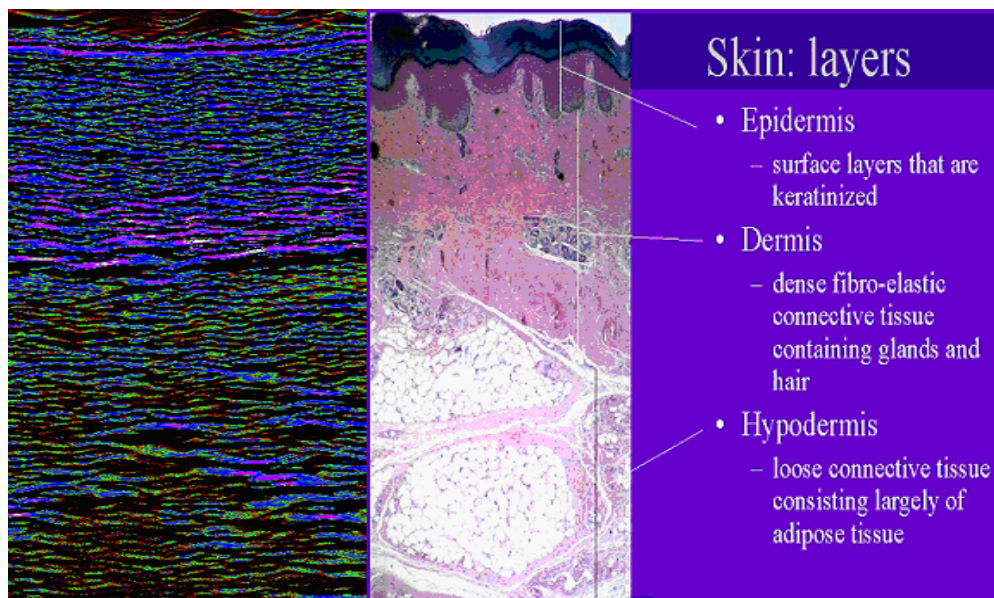
Scans were also taken of the patient's normal skin adjacent to the affected area to get a profile of what the patient's uninjured skin should look like.

Scans of the injured skin was then compared to the scans of the 'normal' skin (fig 2) to give us a measure of how far from normal the tissues were at the start of the study and how they then progressed back towards the normal profile as the study advanced.

### Scan Analysis

Using the scanners image analysis software it was possible to measure the amount of oedema within the dermal tissue. Each scan of the tissue was analysed using a form of pixel distribution analysis whereby pixels below certain intensity are classed as Low Echogenic Pixels (LEP). The ratio of LEP's to Total Pixel count (TP) has been shown to reflect changes in dermal water content (7, 8, 9). Using this technique it was possible to get a quantitative assessment of the level of oedema present in the damaged tissue.

Figure 2 scan of normal skin with adjacent histology section indicating zones

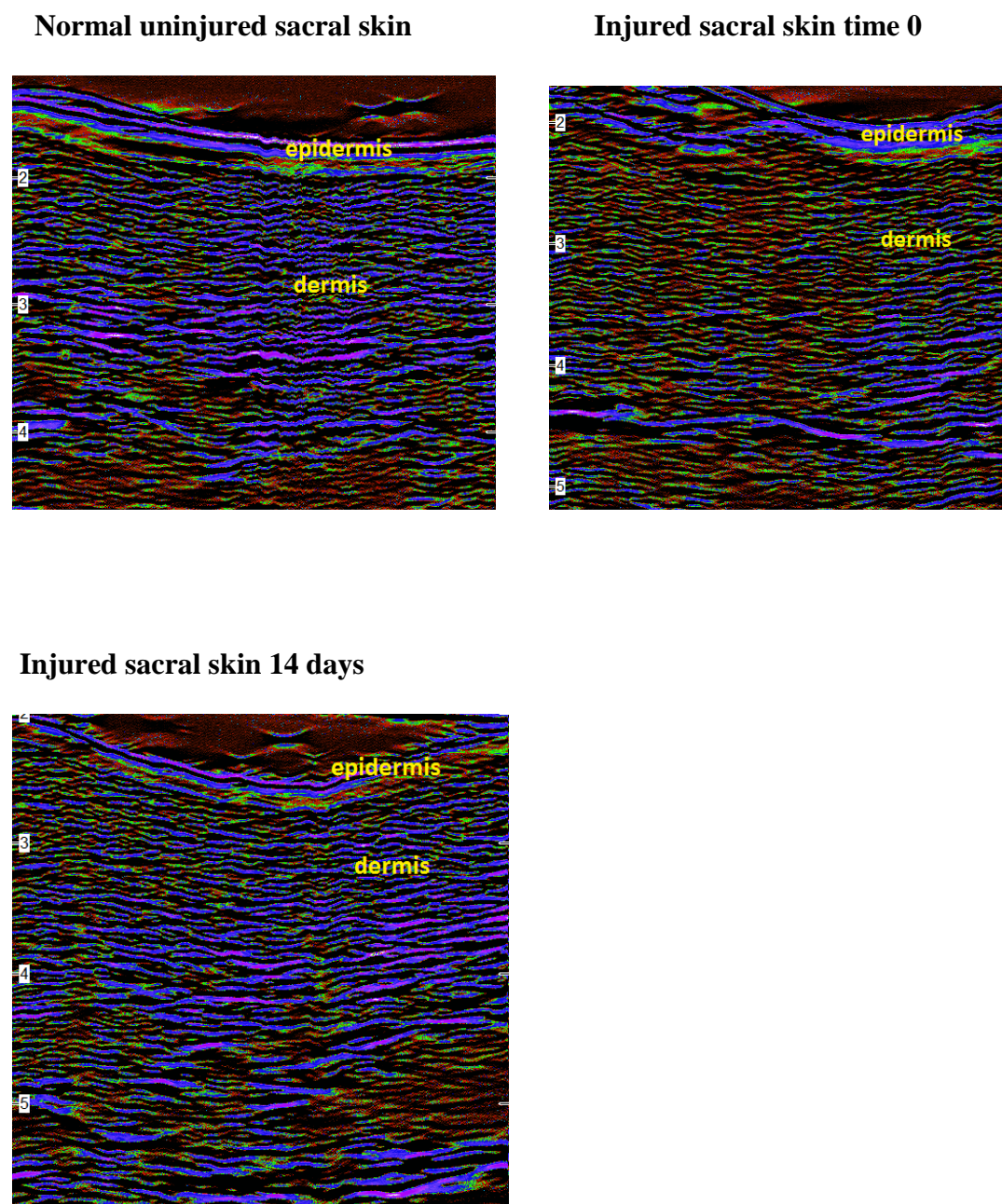


## **Results**

The following section shows the individual patient scans for all time points.

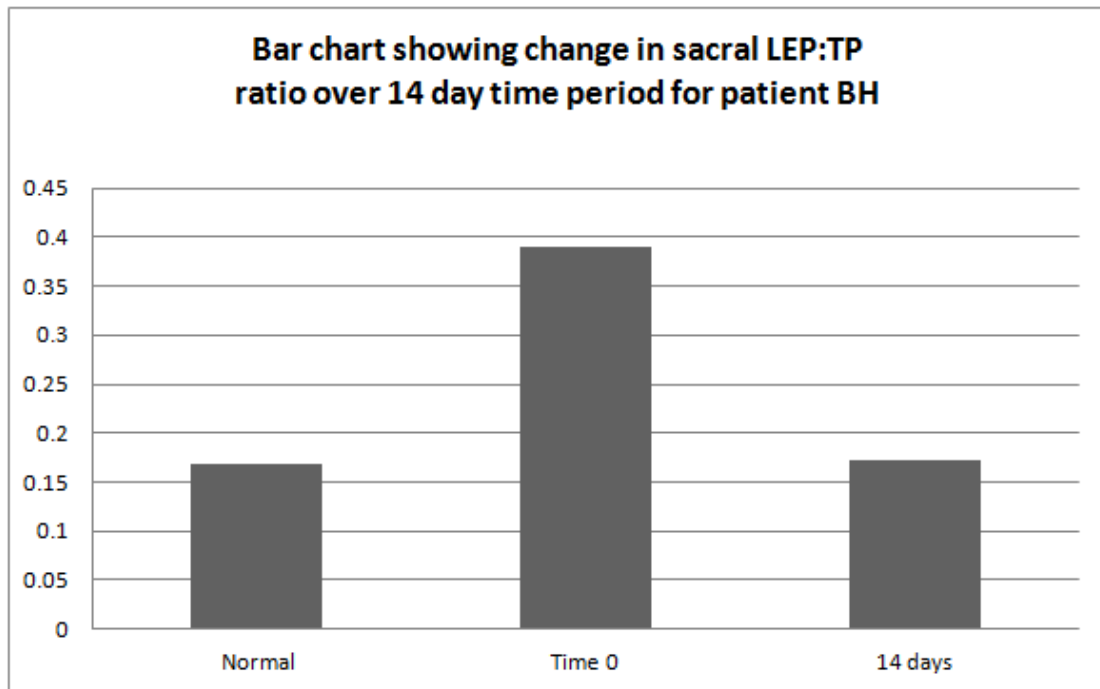
### **Results – BH**

Figure 3. Scans comparing the patient's normal skin with the damaged site.



The injured tissue at time 0 has an elevated level of red pixels in the scan, compared to the uninjured skin, indicating the presence of oedema. The scan of the same tissue after 14 days shows the red pixels appear to have decreased and there is an increase in blue pixels.

Figure 4 Graph of LEP: TP ratio for BH Analysis

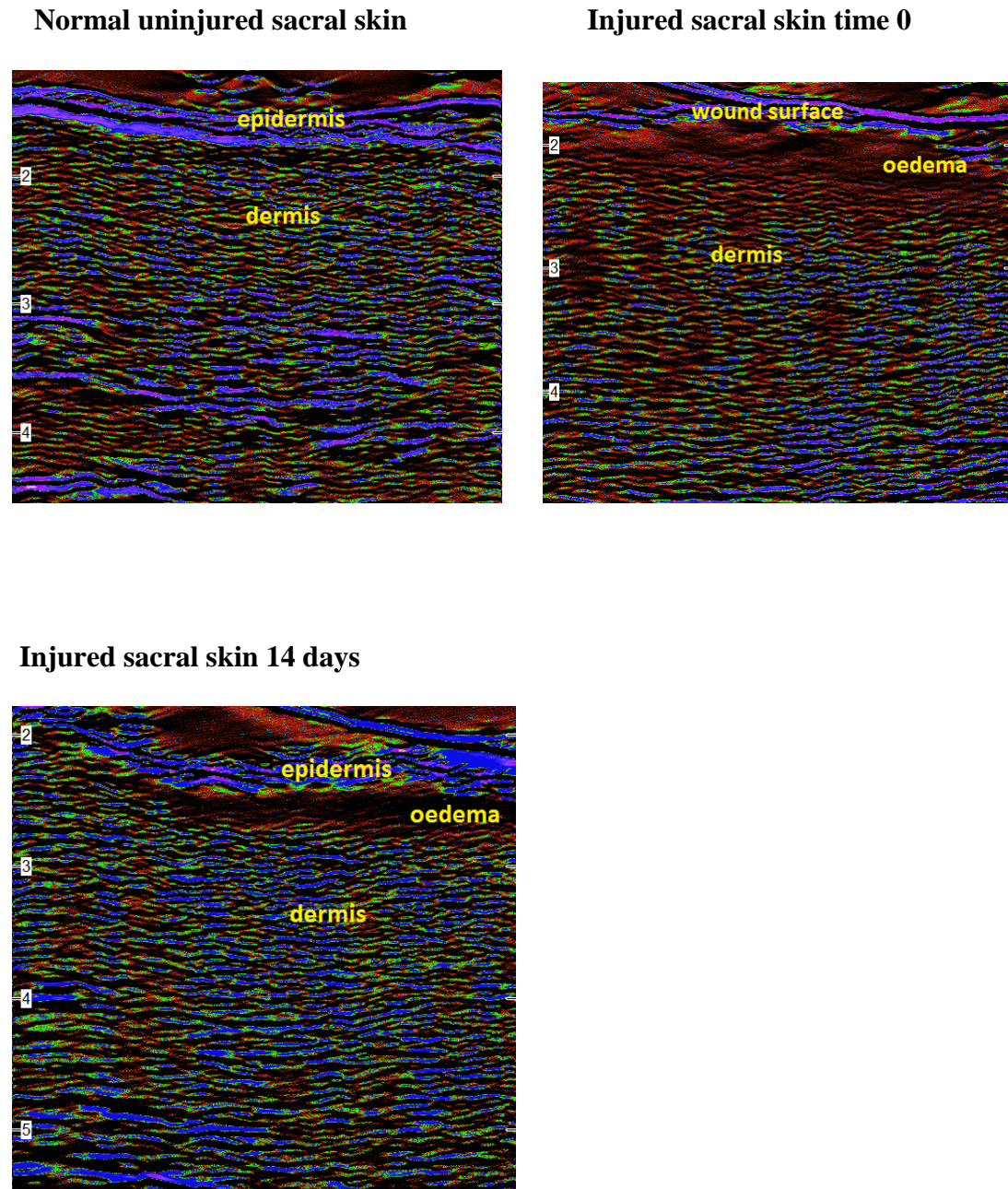


The graph above shows that the injury site at time zero has a much larger LEP:TP ratio value than that of the uninjured skin. This is due to the high levels of oedema present in the skin. After 14 days the ratio level has decreased towards the normal levels as the oedema has decreased.



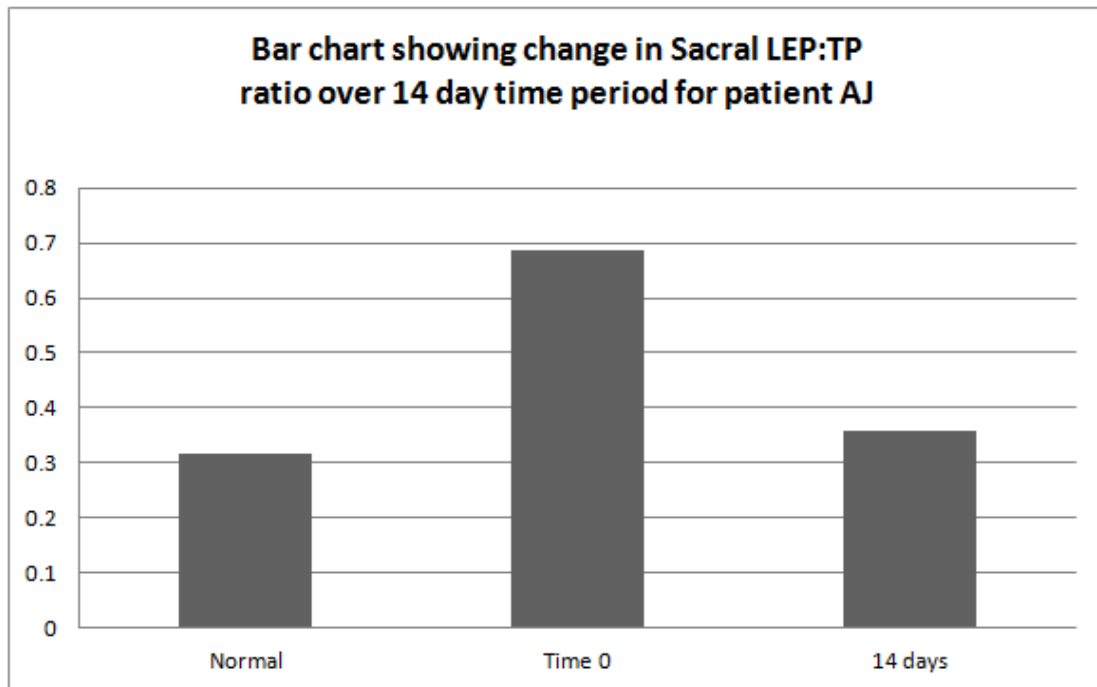
## **Results – AJ**

Figure 5. Scans comparing the patient's normal skin with the damaged site.



The injured tissue at time 0 has an elevated level of red pixels in the scan, compared to the uninjured skin, indicating the presence of oedema. The scan of the same tissue after 14 days shows the red pixels appear to have decreased and there is an increase in blue pixels. It can be noticed that there is still a relatively small zone of oedema just below the epidermis at 14 days which should resolve as treatment continues.

Figure 6 Graph of LEP: TP ratio for AJ Analysis

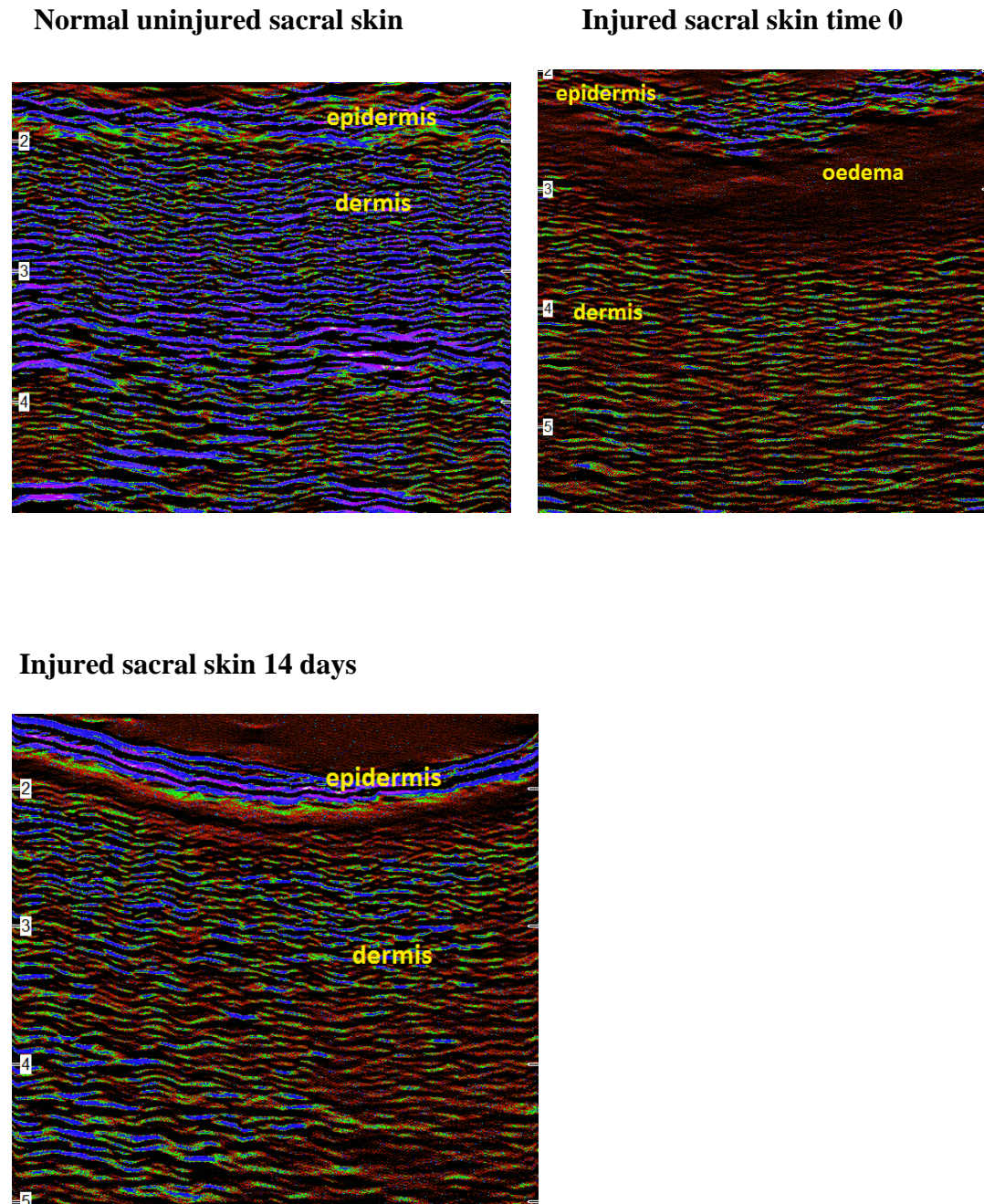


The graph above shows that the injury site at time zero has a much larger LEP:TP ratio value than that of the uninjured skin. This is due to the high levels of oedema present in the skin. After 14 days the ratio level has decreased towards the normal levels as the oedema has decreased.



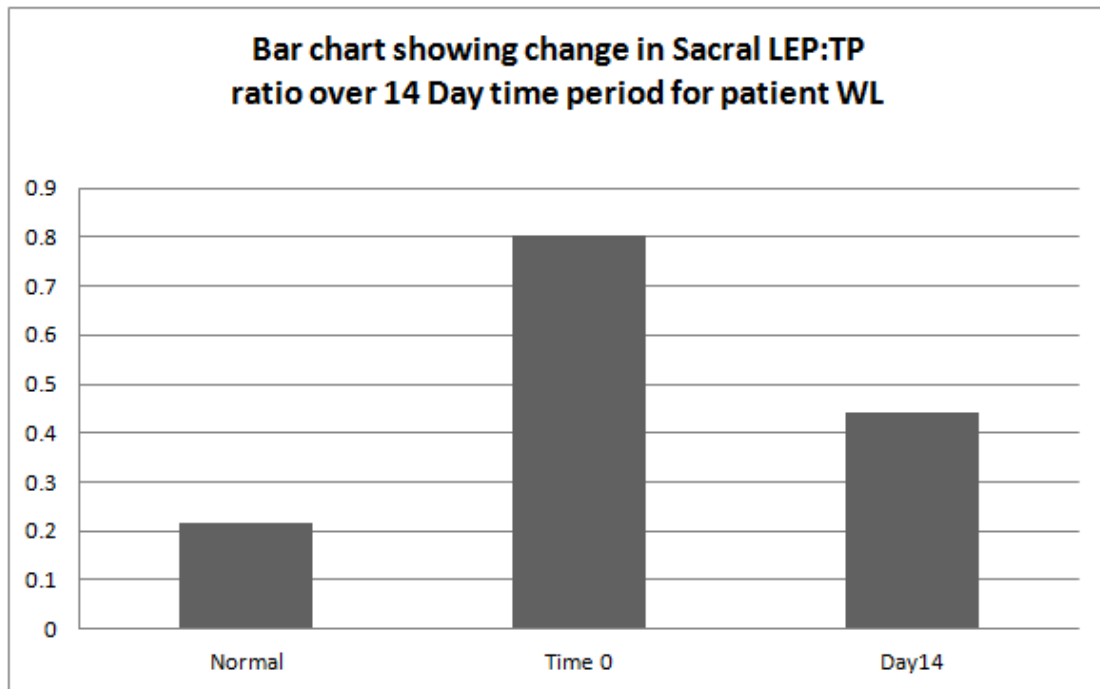
## **Results – WL**

Figure 7. Scans comparing the patient's normal skin with the damaged site.



The injured tissue at time 0 has an elevated level of red pixels in the scan, compared to the uninjured skin, indicating the presence of oedema. The scan of the same tissue after 14 days shows the red pixels appear to have decreased and there is an increase in blue pixels. It can be noticed that there is still a relatively small zone of oedema just below the epidermis at 14 days which should resolve as treatment continues.

Figure 8 Graph of LEP: TP ratio for BL Analysis

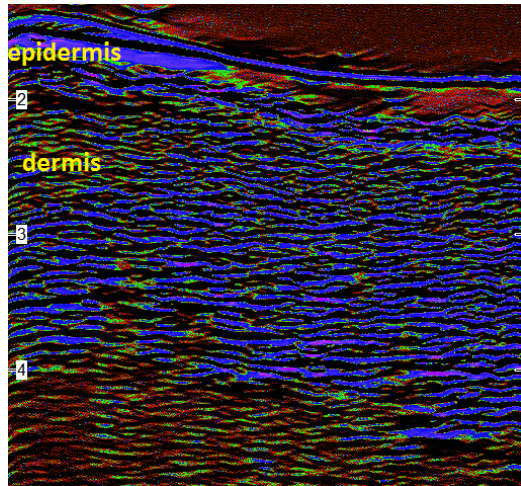


The graph above shows that the injury site at time zero has a much larger LEP:TP ratio value than that of the uninjured skin. This is due to the high levels of oedema present in the skin. After 14 days the ratio level has decreased towards the normal levels as the oedema has decreased.

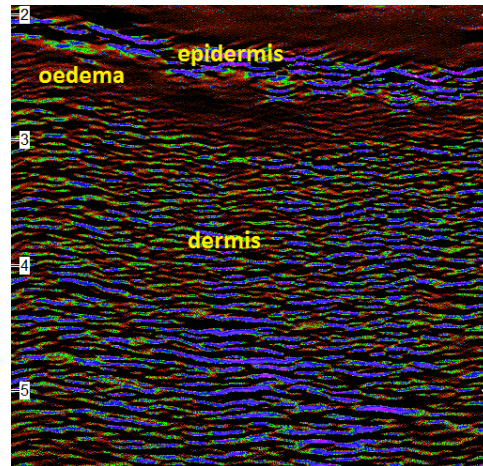
## **Results – CM**

Figure 9. Scans comparing the patient's normal skin with the damaged site.

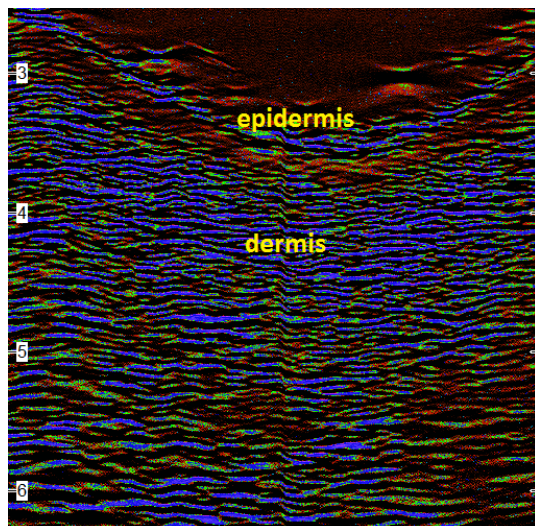
**Normal uninjured sacral skin**



**Injured sacral skin time 0**

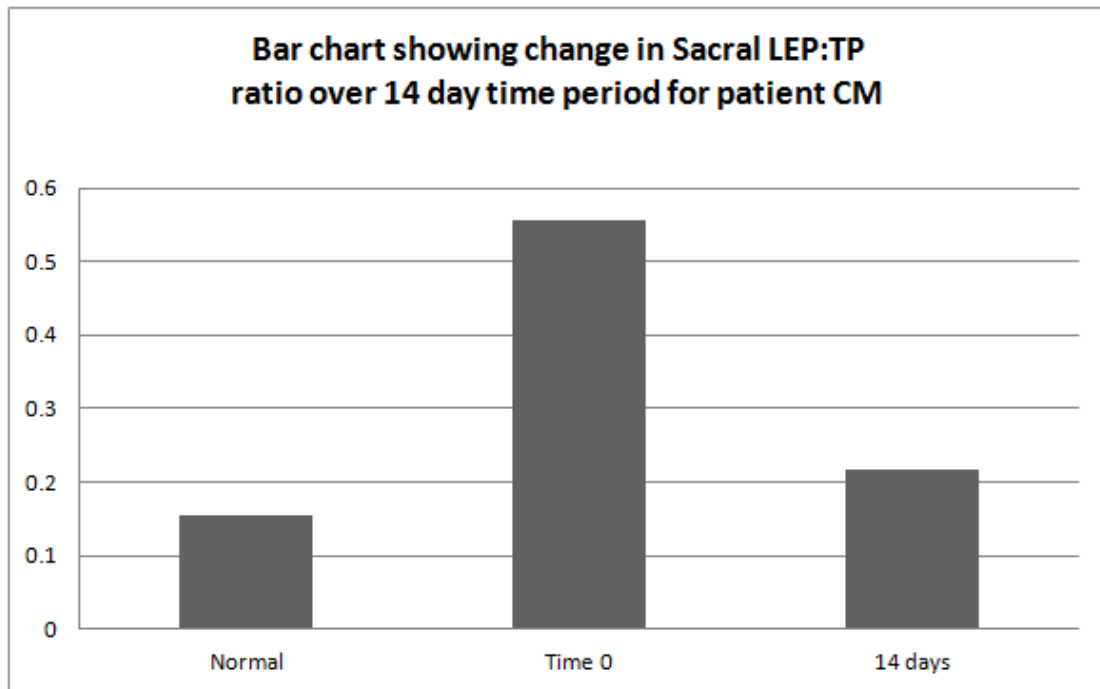


**Injured sacral skin 14 days**



The injured tissue at time 0 has an elevated level of red pixels in the scan, compared to the uninjured skin, indicating the presence of oedema. The scan of the same tissue after 14 days shows the red pixels appear to have decreased and there is an increase in blue pixels. It can be noticed that there is still a relatively small zone of oedema just below the epidermis at 14 days which should resolve as treatment continues.

Figure 10 Graph of LEP: TP ratio for CM Analysis



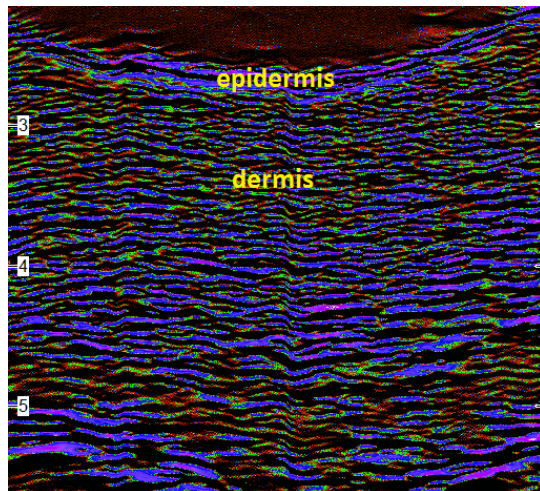
The graph above shows that the injury site at time zero has a much larger LEP:TP ratio value than that of the uninjured skin. This is due to the high levels of oedema present in the skin. After 14 days the ratio level has decreased towards the normal levels as the oedema has decreased.



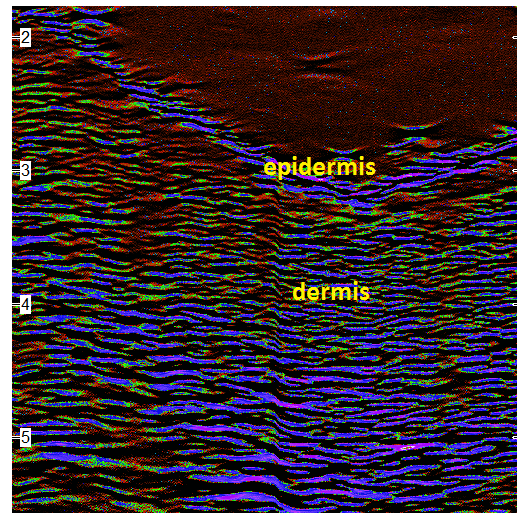
## **Results – SD**

Figure 11. Scans comparing the patient's normal skin with the damaged site.

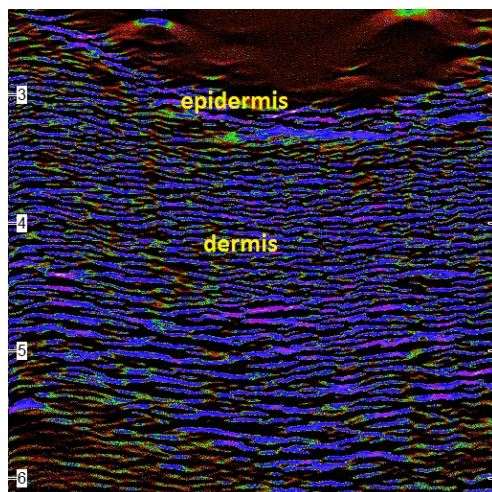
**Normal uninjured sacral skin**



**Injured sacral skin time 0**

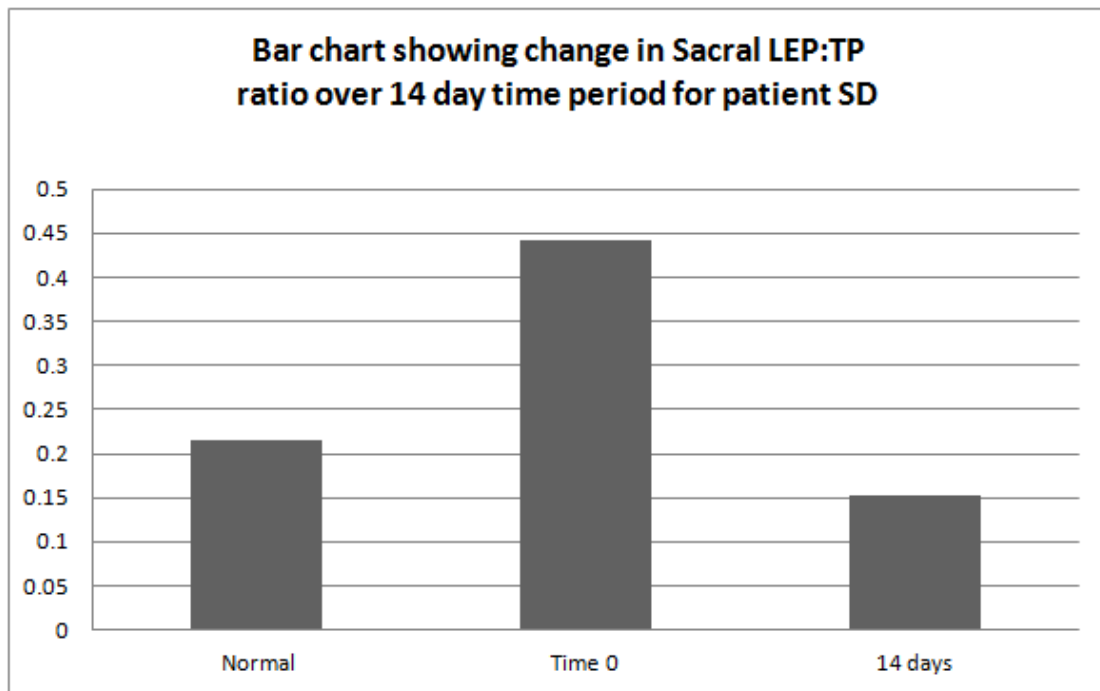


**Injured sacral skin 14 days**



The injured tissue at time 0 has an elevated level of red pixels in the scan, compared to the uninjured skin, indicating the presence of oedema. The scan of the same tissue after 14 days shows the red pixels appear to have decreased and there is an increase in blue pixels.

Figure 12 Graph of LEP: TP ratio for SD Analysis



The graph above shows that the injury site at time zero has a much larger LEP:TP ratio value than that of the uninjured skin. This is due to the high levels of oedema present in the skin. After 14 days the ratio level has decreased towards the normal levels as the oedema has decreased.



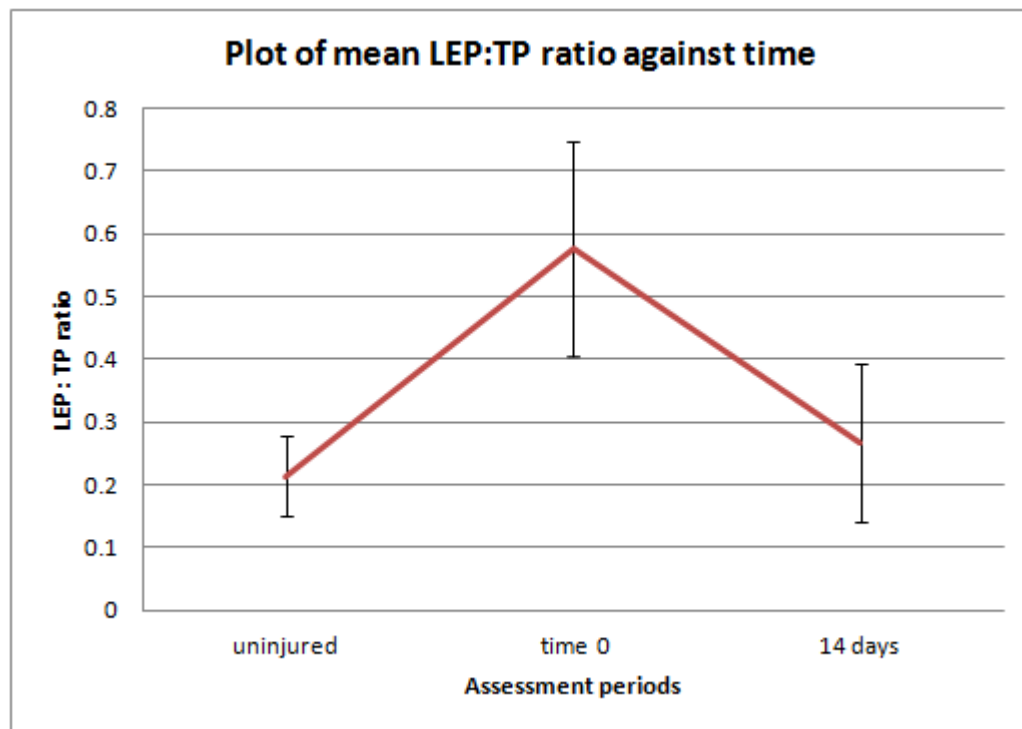
### Mean result data

The mean results for the study are shown in the table below and expressed graphically in figure 13.

These figures represent the mean data for the 5 patients.

Assessment Period	Mean LEP/TP ratio $\pm$ SD
Uninjured skin	$0.214 \pm 0.06$
Time 0	$0.58 \pm 0.17$
14 days	$0.268 \pm 0.13$

Figure 13. Graph showing LEP: TP ratio



The analysis of the ultrasound images from the uninjured skin of the patients shows that the mean LEP: TP ratio is 0.214. This is therefore the level we would wish to get the affected skin to if our therapy works.

As the graph shows, the damaged skin at time 0 is 0.58 which is approximately twice the uninjured skin level, which indicates high levels of oedema present.

By 14 days the ratio is almost at normal/uninjured levels.

## **Conclusion**

The results of the ultrasound scan analysis show that the Stimulite cushions appear to be having a measured effect on tissue recovery, with sacral tissues moving towards their pre-injured state within 14 days after commencing treatment.

## **References**

1. Young SR, Ballard K. Wound Assessment: Diagnostic and assessment applications – Part 2.. In: Electrotherapy-Evidence based practice 2001. Pp308-312. Churchill-Livingstone (London).
2. Chen L, Dyson M, Rymer J, et.al. The use of high frequency diagnostic ultrasound to investigate the effect of HRT on skin thickness. *Skin Research And Technology* 2001; 7(2): 95-7
3. Mirpuri N, Young SR. The use of diagnostic ultrasound to assess the skin changes that occur during normal and hypertensive pregnancies. *Skin Research and Technology* 2001; 7:63-69.
4. Kerr A, Young S, Hampton S. Has packing sinus wounds become a ritualistic practice? *British Journal of Nursing* 2006; 15(19): S27-S30.
5. Quintavalle P, Lyder CH, Mertz PJ, et.al. Use of high-resolution, high frequency diagnostic ultrasound to investigate the pathogenesis of pressure ulcer development. *Adv. Skin & Wound Care* 2006; 19(9):498-505.
6. Young S, Bolton PA, Downie J. Use of high-frequency ultrasound in the assessment of injectable dermal fillers. *Skin Research and Technology* 2008;14: 1-4.
7. Gniadecka M. Localization of dermal edema in lipodermatosclerosis, lymphedema, and cardiac insufficiency: high-frequency ultrasound examination of intradermal echogenicity. *J Am Acad Dermatol.* 1996; 35:37-41.
8. Gniadecka M, Quistorff B. Assessment of dermal water by high-frequency ultrasound: comparative studies with nuclear magnetic resonance. *Br J Dermatol.* 1996; 135:218-224
9. Young. S, Hampton. S, and Tadej. M. Study to evaluate the effect of low-intensity pulsed electrical currents on levels of oedema in chronic non-healing wounds. *Journal of Wound Care* 2011; 20:368-373